

***TREATMENT OF ADVANCED PELVIC  
OSTEOSARCOMA WITH  
CHEMOTHERAPY DIRECTLY  
INSIDE THE TUMOR. CASE REPORT.***

**E.Guikov, S. Alkallaf, B. Markowska,  
H.Cornille, I.M. Bigirimana,  
G.Delépine, Nicole Delépine.**

[www.nicoledelepine.fr](http://www.nicoledelepine.fr)



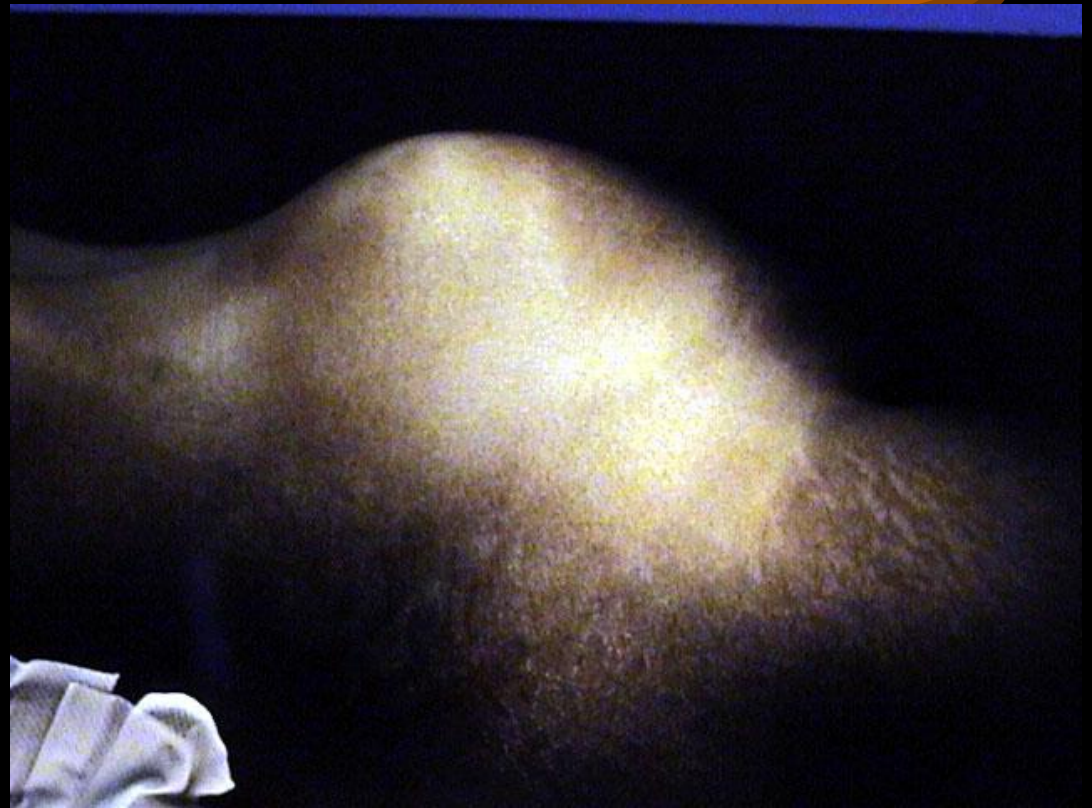# *Introduction*

**Very large tumors of pelvis often seem inoperable and are treated by palliative radiotherapy and/or chemotherapy.**


**We present here a case with intratumoral chemotherapy and mid-term result.**

# *This girl, 16 years old*

**came from Africa  
in 2000 July, for  
a huge tumor of  
pelvis after 2  
years of pelvic  
pain.**



*August 2000. needle biopsy*

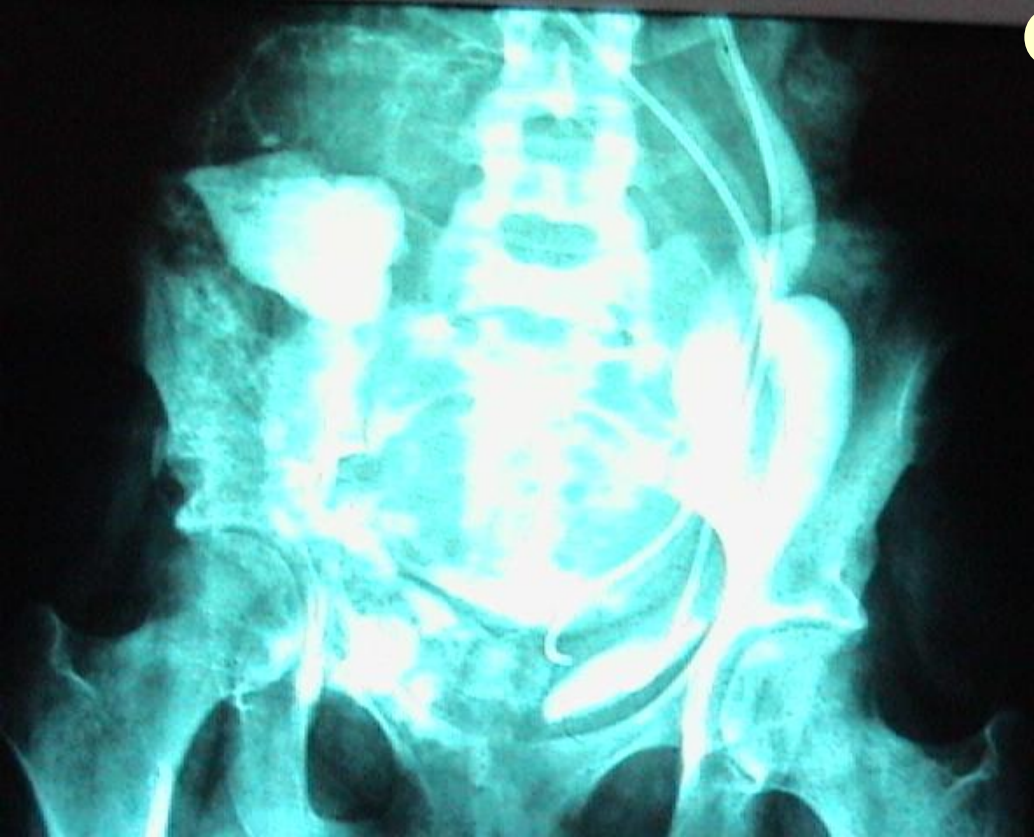

**confirmed the  
diagnosis of high  
grade osteosarcoma.**

**No distant metastase  
was seen on bone and**

**scan**

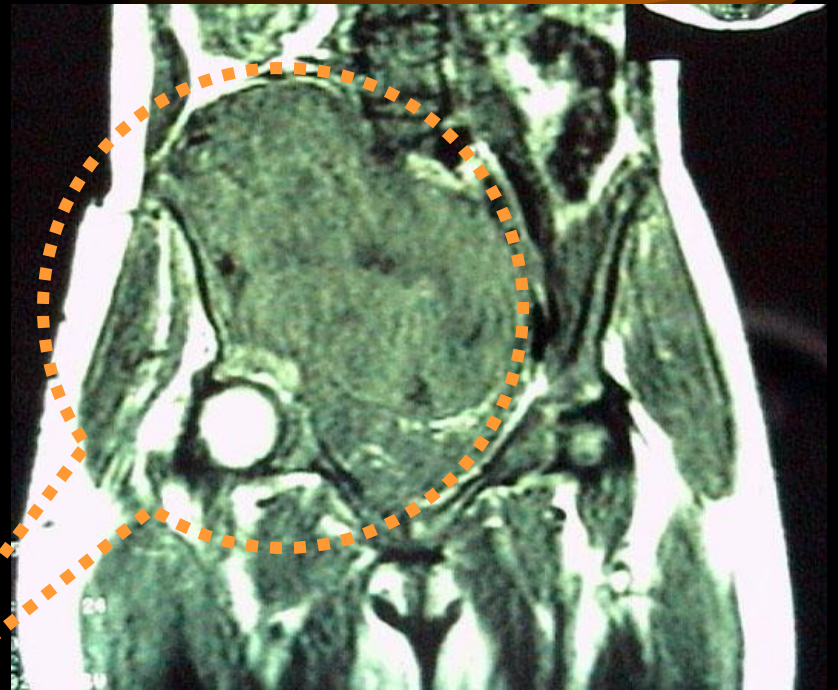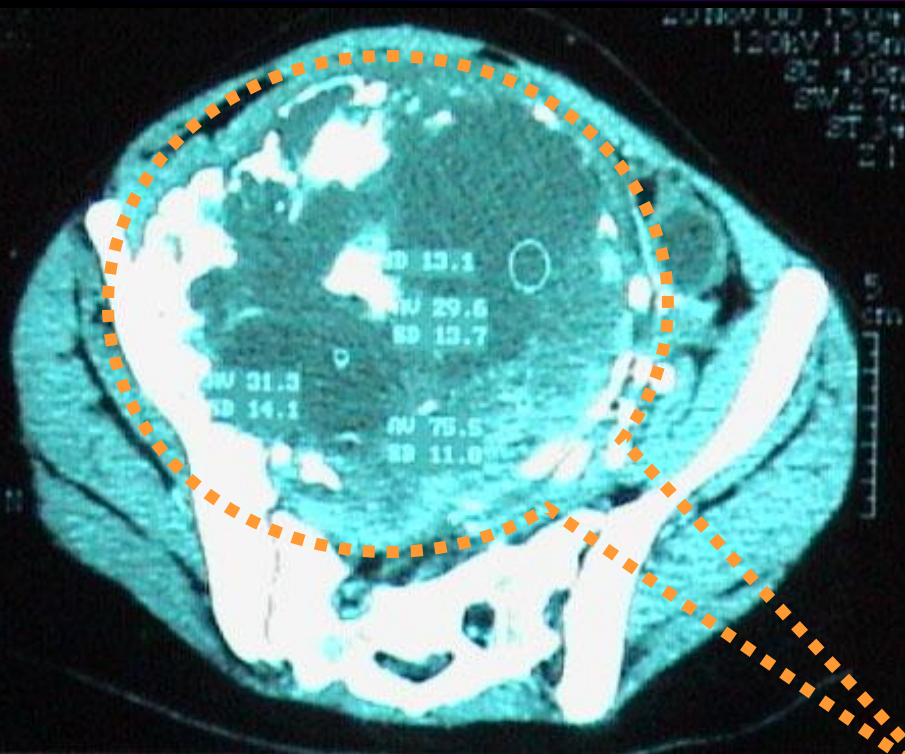
*Conventional chemotherapy didn't  
obtain any objective response.*



**Conventional chemotherapy  
performed in another center  
didn't obtain any objective  
response.**

**As no carcinologic surgery  
seemed possible **the patient  
was sent in a palliative care  
unit** after 2 months of an  
**ineffective treatment.****

*October 2000 she came to our unit*



**Initial screening showed a huge tumor (15 cm x 12 x 10) developed from the right acetabulum, with compression of bladder and ureters.**

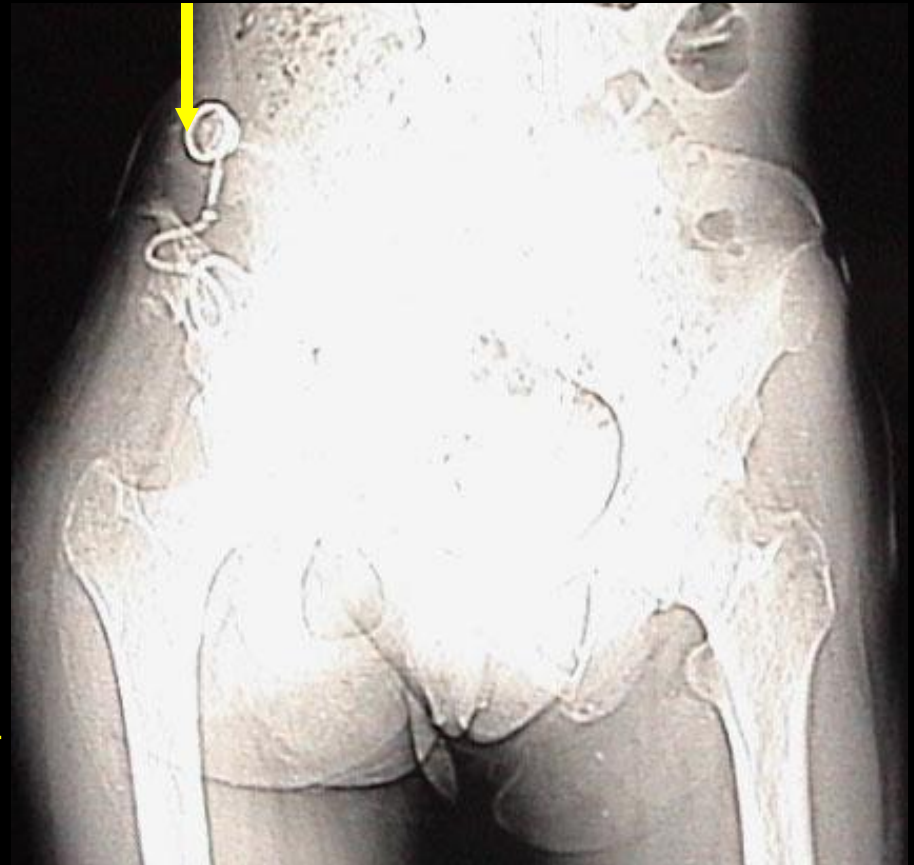
# October 2000

**After intratumoral  
curettage**

**We started both**

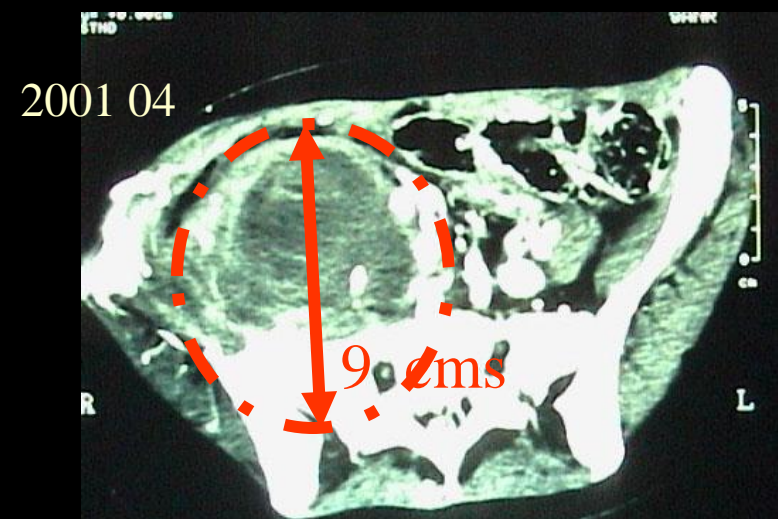
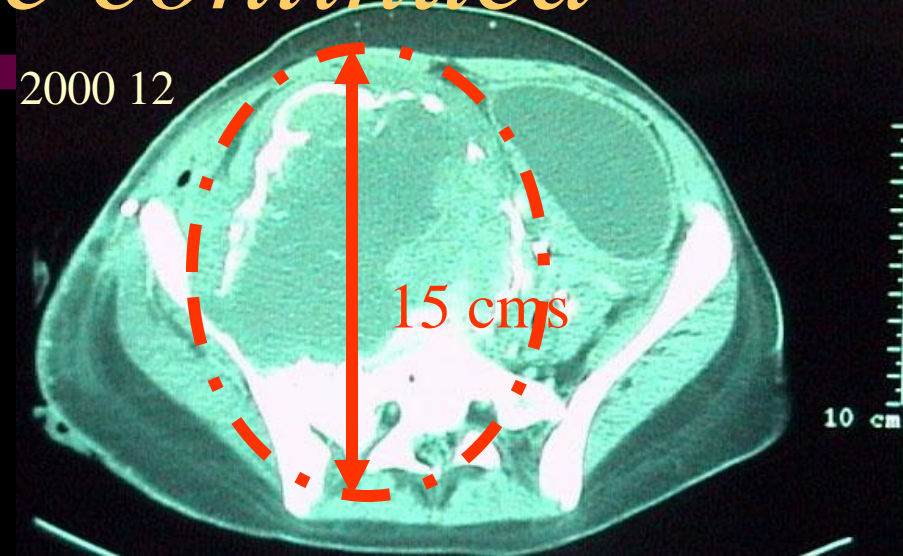
- **general and**
- **local chemotherapy  
infused directly inside  
the tumor cavity through  
an infusion catheter.**

**Catheter pour infusion of  
chemotherapy directly inside the  
tumoral cavity**



*Both intra-tumor and intravenous chemotherapy were continued*

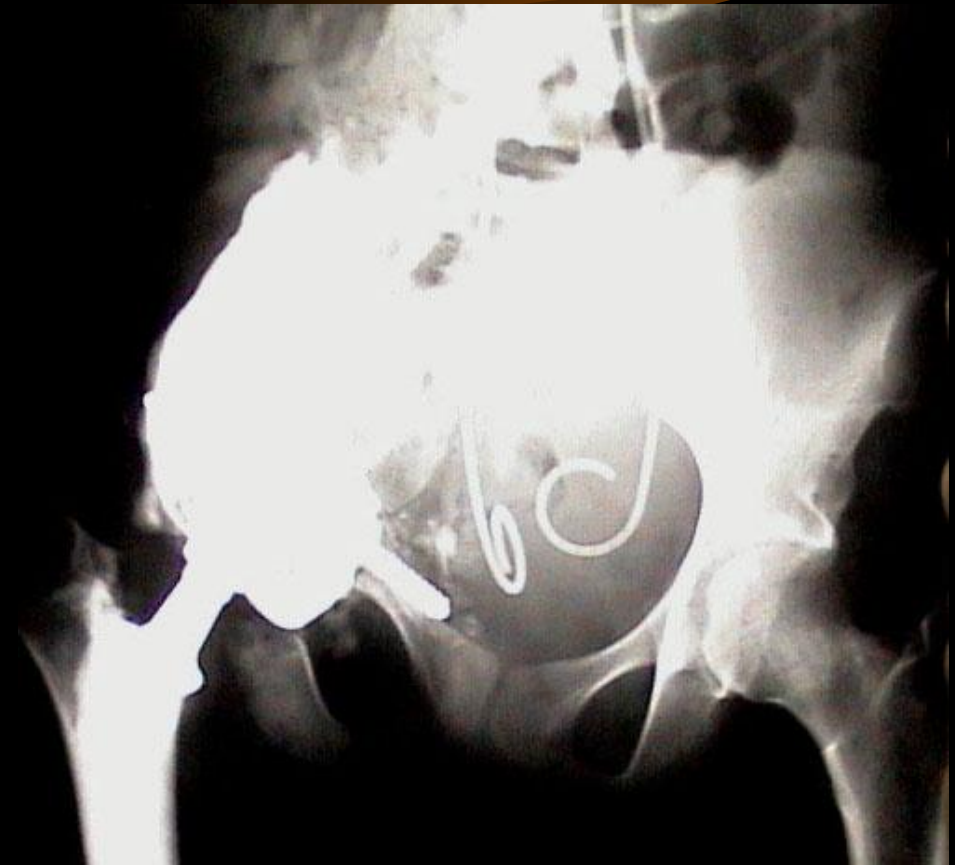We observed an impressive **tumoral shrinkage (75% of initial tumoral volume)** new debulking surgery was performed and the urinary tract could be repaired.





*October 2001*

**The last tumor residual was removed and a composite acetabular reconstruction performed.**



*One year after surgery the hip function rated according to Enneking's criteria is excellent.*



# *Oncologic Result*

**In april 2003,  
30 months after she was  
considered to have a life  
expectancy less than 1  
month ,the patient is in  
complete remission.**

**She can walk,  
go to school and live  
normally.**



# *Conclusion*

**Advanced sarcoma can sometimes benefit of an individualized treatment including intratumoral chemotherapy.**

**« les seuls combats perdus d 'avance sont ceux qu 'on ne livre pas »**